

INTERESTING CASE: ACHILLES PERITENDINOSIS

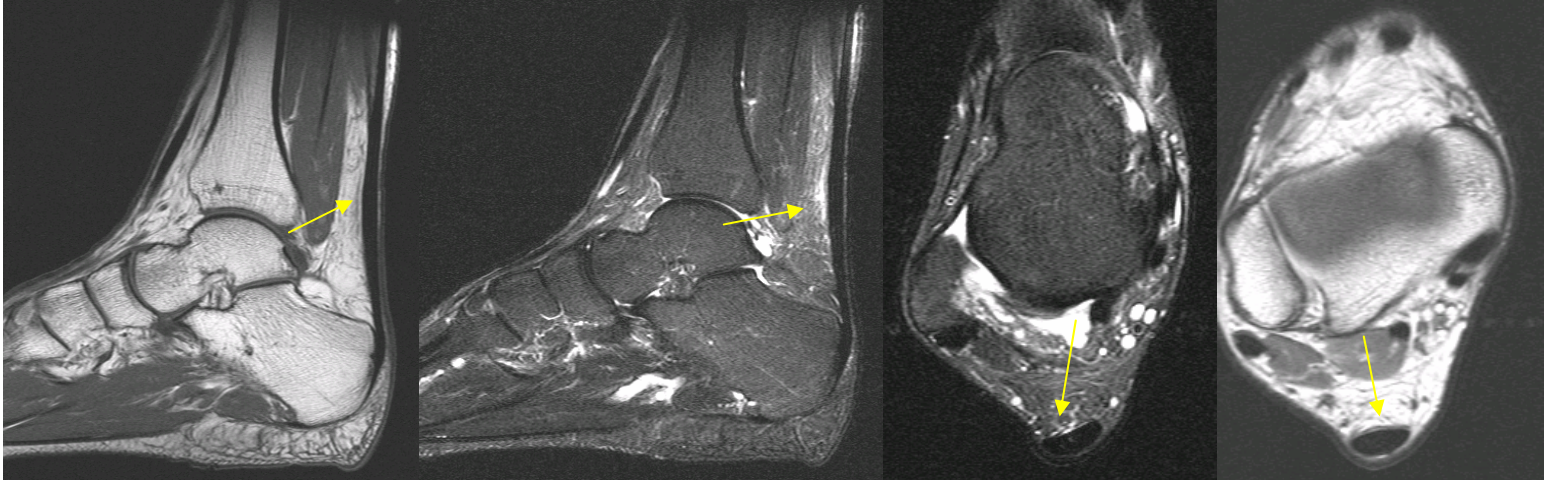


Fig. 1a

Fig. 1b

Fig. 2a

Fig. 2b

Clinical Presentation: This is a 35-year-old male who was referred to AIC for pain over the Achilles tendon. An MRI of the Ankle was performed on a 1.5 Tesla Siemens Symphony Magnet.

Imaging Findings: There is mild fusiform thickening of the Achilles tendon (arrow, **Fig. 1a**), with the maximum diameter occurring about 5 cm. proximal to its insertion, and subtle anterior convexity of the tendon at this point (arrow, **Fig. 2b**). Subtle minimal foci of increased signal on T1 and proton density images are present. There is mild amount of hyperintensity on FLAIR images anterior to the Achilles tendon in this region consistent with edema within the pre-Achilles fat pad (arrows, **Fig. 1b, 2a**). There is no evidence for an Achilles tendon tear.

Diagnosis: These findings are compatible with **Achilles peri-tendinosis** and mild **Achilles tendinosis** without a tear.

Discussion: The Achilles tendon lacks a tendon sheath, but has a peritenon whose vascular system extends both within and outside the tendon. Achilles peritendinosis demonstrates linear or irregular areas of altered signal intensity in the pre-Achilles tendon fat pad consistent with edema or scarring of the peritenon. The tendon itself is normal. Achilles tendinosis manifests on axial MR images as loss of the anterior concave or flat surface of the Achilles tendon and on sagittal images as fusiform thickening of the tendon with possible areas of increased signal intensity within the tendon.

Treatment: Initially, conservative therapy will suffice. More advanced cases may require surgical intervention.

For more information or any concerns, please contact me directly.

Ray Hashemi, MD
Ray H. Hashemi, M.D., Ph.D.
Director

REFERENCE: Zehava S. Rosenberg, MD, et. Al., MR Imaging of the Ankle and Foot. *Radiographics*. 2000;20:S153-S179.